

## Intraoperative Antiaggregant Strategy for Off-Pump Coronary Artery Bypass Grafting in a Patient with Heparin-Induced Thrombocytopenia

Marco Zanobini,<sup>1</sup> Fabio Barili,<sup>1</sup> Francesco Alamanni,<sup>1</sup> Luca Dainese,<sup>1</sup> Vincenzo Stringi,<sup>1</sup> Antioco Cappai,<sup>1</sup> Margherita Dell'Orto,<sup>2</sup> Massimo Porqueddu,<sup>1</sup> Maurizio Roberto,<sup>1</sup> Samer Kassem,<sup>1</sup> Giulio Pompilio,<sup>1</sup> Paolo Biglioli<sup>1</sup>

<sup>1</sup>Department of Cardiac Surgery, University of Milan, Milan, Italy; <sup>2</sup>Department of Cardiology, S. Pio X Hospital, Milan, Italy

### ABSTRACT

Immune heparin-induced thrombocytopenia is a rare complication of heparin administration. We describe a patient with a previous diagnosis of heparin-induced thrombocytopenia and related contraindications to anticoagulation who underwent urgent off-pump myocardial revascularization with the administration of only antiaggregant therapy.

### INTRODUCTION

Immune heparin-induced thrombocytopenia (type II HIT) is a rare complication of heparin administration, occurring in 3%-5% of patients [Cancio 1998]. Type II HIT is determined by immunologic mechanisms and reflects an activation of the coagulation system through platelet activation, endothelial activation, and heparin-neutralization. It can affect the postoperative course, leading to life-threatening thrombosis [Spinler 2006].

In patients with known HIT, heparin administration, as well as administration of heparin analogues, must be avoided. Diverse anticoagulant protocols have been reported for patients with HIT who undergo cardiac surgery [Carr 2005]. Anticoagulation therapy cannot be administered in every patient, however, and relative contraindications can exist.

We describe a patient with a previous diagnosis of type II HIT and relative contraindications to anticoagulation who underwent off-pump myocardial revascularization with antiaggregant therapy only.

### CASE REPORT

On September 2005, a 49-year-old white man was admitted to our hospital with unstable angina. He had a previous diagnosis of type II HIT, made after the onset of a severe

heparin-related thrombocytopenia and disseminated intravascular coagulation during a hospitalization for orthopedic surgery and confirmed by the results of a C-serotonin release test and enzyme-linked immunosorbent assay for serum antibodies to heparin-PF4 complexes. Further associated diseases included hypertension, chronic renal failure (preoperative creatinine 3.3 mg/dL), hepatitis C virus (HCV)-related chronic diffuse cirrhosis, and moderate thrombocytopenia (platelet count of  $58 \times 10^9/L$ ).

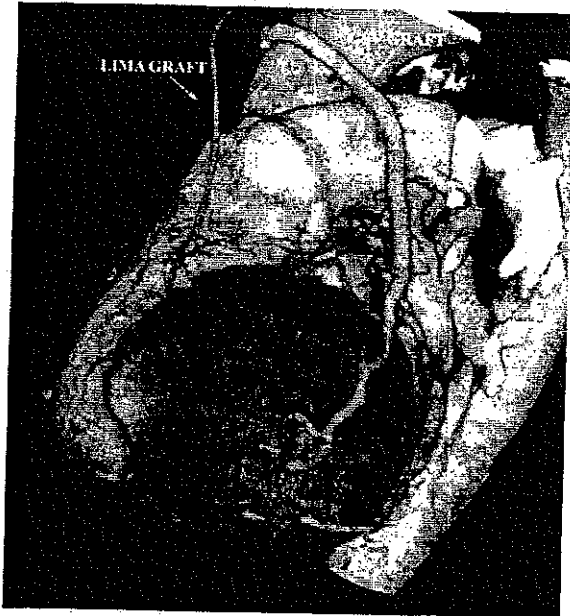
Coronary angiography showed severe bivessel coronary disease not amenable to angioplasty, and the patient was scheduled for urgent surgical myocardial revascularization the day after coronary angiography. At hospital admission, the patient was on 100 mg acetylsalicylic acid therapy that was not discontinued before surgery.

Because of the presence of copathologies that may contraindicate anticoagulant administration, we used an off-pump strategy with an antiaggregant protocol, avoiding heparin and other anticoagulants. The antiaggregant protocol and surgical strategy were chosen by a multidisciplinary task force composed of surgeons, anesthesiologists, hematologists, and cardiologists. The protocol included the administration of 450 mg clopidogrel and 900 mg lysin acetylsalicylate acid 12 hours before surgery and repeated during surgery, 900 mg lysin acetylsalicylate 24 hours after surgery, and 300 mg acetylsalicylic acid and 150 mg ticlopidine once a day until discharge.

Myocardial revascularization was performed off-pump with a beating heart. After vessel harvesting, the left thoracic artery and saphenous vein were not removed from their sites until the coronary arteries were opened. Left anterior descending artery (LAD) revascularization was done first. The anterior wall was stabilized using an Octopus tissue stabilizer (Medtronic, Inc, Minneapolis, MN, USA) and the left internal thoracic artery (LITA) was distally interrupted. The LAD was opened, a 2.0-mm shunt was inserted, and the LITA was anastomosed as usual. From LITA interruption to the conclusion of the anastomosis, LITA blood flushes were done every 10-15s. Anastomosis between the marginal branch and saphenous vein was performed in the same fashion, after exposing the lateral wall through a LIMA stitch, performing the proximal anastomosis first and washing the anastomosis site continuously with a solution containing acetylsalicylic acid. Distal anastomosis on the

Received July 17, 2007; received in revised form October 12, 2007; accepted November 7, 2007

Correspondence: Fabio Barili, Department of Cardiovascular Surgery, University of Milan, Centro Cardiologico Monzino IRCCS, Via Parea 4, 20138 Milan, Italy; (e-mail: [fabarili@libero.it](mailto:fabarili@libero.it)).



Multislice computed tomography of the patient's coronary arteries at 6-month follow-up shows patency of the grafts. LIMA indicates left internal mammary artery; GSV, greater saphenous vein.

marginal branch was performed after insertion of a 1.75-mm shunt. During distal anastomosis, blood flushes in the saphenous vein were performed every 10-15s to avoid thrombi formation.

Perioperative blood loss was 220 mL, and no transfusions were required. The postoperative stay was uneventful and the patient was discharged 6 days after surgery. At discharge, 100 mg acetylsalicylic acid therapy was initiated. At 6-month follow-up, multislice computed tomography of coronary arteries showed patency of the grafts (Figure).

## DISCUSSION

Management of patients with type II HIT who must undergo cardiac surgery can be challenging. Different anticoagulation protocols have been proposed in these

patients with contraindication to heparin, but perioperative management is not simple or safe [Carr 2005]. Hirudin has a long half-life, is potentially antigenic, and does not have an antagonist [Merry 2004]. Argatroban can induce a hypercoagulable state if acutely suspended. Moreover, the use of these drugs may be contraindicated in some cases, such as renal insufficiency and thrombocytopenia [GUSTO 1996].

We describe the unusual case of a patient needing urgent coronary revascularization who showed simultaneous type II HIT and relative contraindications to anticoagulation. This patient underwent off-pump coronary surgery with antiaggregant therapy. Because of associated HCV-related chronic diffuse hepatopathy, thrombocytopenia, and chronic renal failure, anticoagulation was avoided and double antiaggregation with clopidogrel and lysin acetylsalicylate was chosen. In this very unusual case, no operative complications occurred, and the good operative results were underscored by multislice computed tomography that showed patency of the grafts. These results should not be generalized, however, and may not be applicable to other cases. This strategy was adopted as the last resort in this case, for which other alternatives strategies for effective anticoagulation were not available.

Although in this case the association between off-pump surgery (with some technical modifications such as graft flushing) and double antiaggregant was safe and provided good medium-term results with good patency of the grafts after surgery, further investigation of the safety of this approach is needed, and it should be considered only in very selected cases as a rescue technique in the absence of safer alternatives.

## REFERENCES

- Cancio LC, Cohen DJ. 1998. Heparin-induced thrombocytopenia and thrombosis. *J Am Coll Surg* 186:76-91.
- Carr CS, Rayner A, Ponte J, Desai JB. 2005. Off-pump coronary artery bypass grafting in a heparin-induced thrombocytopenia type II patient using hirudin. *Ann Thorac Surg* 79:696-8.
- Merry AF. 2004. Bivalirudin, blood loss, and graft patency in coronary artery bypass surgery. *Semin Thromb Hemost* 30:337-46.
- Global Use of Strategies to Open Occluded Coronary Arteries (GUSTO) IIb investigators. 1996. A comparison of recombinant hirudin with heparin for the treatment of acute coronary syndromes. *N Engl J Med* 335:775-82.
- Spinler SA. 2006. New concepts in heparin-induced thrombocytopenia: diagnosis and management. *J Thromb Thrombolysis* 21:17-21.